

A Clinicopathological Evaluation of Oral Cavity Lesions and the Role of Cytokeratin 8/18 as a Marker in Oral Premalignant and Malignant Lesions: A Hospital-based Cross-sectional Study

NIRMALI MATTACK¹, BALMIKI DATTA², BARNALI DAS³, GITALI DEVI⁴

ABSTRACT

Introduction: The oral cavity is affected by a wide range of pathologic lesions that may originate from squamous mucosa, salivary glands, mesenchymal structures and lymphoid tissue. Alterations in Cytokeratin (CK) patterns have been reported in oral potentially malignant and malignant lesions, and its expression is a hallmark of tumour progression.

Aim: To evaluate different oral cavity lesions, with an emphasis on using Cytokeratin 8/18 (CK8/18) to differentiate between benign, premalignant and malignant lesions.

Materials and Methods: The present hospital-based cross-sectional observational study was conducted in the Departments of Pathology and Otorhinolaryngology, Fakhruddin Ali Ahmed Medical College and Hospital, Barpeta, Guwahati, Assam, India, from September 2020 to August 2021. A total of 93 biopsied or resected specimens clinically presenting in the Otorhinolaryngology Department with oral cavity lesions were submitted to the Department of Pathology, Fakhruddin Ali Ahmed Medical College and Hospital for histopathological examination followed by Immunohistochemistry (IHC) with CK8/18 in all the tissue samples as per IHC protocol. Age, gender, clinical presentation and sites of lesions were also assessed, as well as, histopathological evaluation and IHC. All data were collected, compiled and subjected to suitable statistical analysis, such as one-way Analysis of Variance (ANOVA) and Fisher's exact tests using International Business Machines (IBM) Statistical Package for Social Sciences (SPSS) software version 28.0. Microsoft Office Word and Excel 2019 were used to generate graphs and tables.

Results: The age of the patients ranged from 9-90 years and mean±Standard Deviation (SD) age was 52.69±15.81 years. Males, 59 (63.4%), were more commonly affected than females 34 (36.6%), with a male-to-female ratio of 1.73:1. Among the 93 various oral cavity lesions, 24 were located on the buccal mucosa, making it the most common site in our study. Of the 42 malignant oral cavity lesions, the most frequent was moderately differentiated Squamous Cell Carcinoma (SCC) with a frequency of 21 cases (50%), followed by well-differentiated SCC with 18 cases, including one case of Verrucous carcinoma. Poorly differentiated SCC was the least frequent, with three cases (7.14%). CK8/18 was positive in 33 of the 42 malignant cases, four out of the 20 dysplasia cases, and all the benign cases were negative for IHC of CK8/18. The maximal intensity of CK8/18 was seen in 13/21 (62%) cases of moderately differentiated oral SCC.

Conclusion: In conclusion, the present study on oral cavity lesions in the lower Assam region highlighted the significance of clinical, histopathological and immunohistochemical evaluations, particularly with CK8/18 staining. A predominance of lesions on the buccal mucosa was found, with moderately differentiated SCC being the most common malignant type. CK8/18 expression showed a notable association with malignant lesions, especially in moderately differentiated SCC, suggesting its potential as a diagnostic marker. These findings contribute to a better understanding of oral cavity pathologies and may aid in early detection and management strategies.

Keywords: Cytokeratins, Dysplasia, Squamous cell carcinoma

INTRODUCTION

Oral cancer, also referred to as mouth cancer, is a type of malignancy that impacts the oral cavity [1]. The oral cavity serves as the entry point for the digestive and respiratory tracts. The mucous membrane of the mouth consists of squamous epithelium covering the vascularised connective tissue. The epithelium is keratinised over the hard palate, lips and gingiva, while elsewhere, it is non keratinised [2,3].

The oral cavity can be affected by a wide range of pathologic lesions that may originate from squamous mucosa, salivary glands, mesenchymal structures and lymphoid tissue. Various lesions can occur within the oral cavity, including inflammatory, cystic, benign, premalignant, potentially malignant and malignant neoplasms [4].

Oral cancers often develop from oral premalignant lesions such as oral leukoplakia, Oral Submucous Fibrosis (OSMF) and oral erythroplakia,

which can be easily detected clinically by healthcare professionals. The malignant transformation rate of oral leukoplakia ranges from 0.13-17.5%, and that of OSMF varies from 4.5-7.6%. Thus, early detection and evaluation of these oral precancers can play a significant role in preventing their progression into invasive oral cancer [5].

Squamous cell carcinoma represents the vast majority (90%) of malignant oral neoplasms [6]. In parts of India, oral cancer can account for more than 50% of all cancers. It is the most common cancer among males and the third most common among the female population, which is related to deleterious oral habits such as tobacco chewing, betel-quid chewing, tobacco smoking, reverse smoking, as well as, other factors such as alcohol consumption, low socio-economic status, poor oral hygiene, poor diet and viral infections, chronic irritation from ill-fitting dentures, rough, or fractured teeth [7]. SCC of the oral cavity is a major health concern in the Northeast

region of India [8]. Furthermore, the high-risk Human Papillomavirus (HPV), mainly HPV 16, has been linked to the development of oropharyngeal cancer [9,10].

Cytokeratins are the major intermediate filaments in squamous epithelium and are critical for cell stabilisation, shape, intracellular signaling and transport [9]. They are essential cytoskeleton components and excellent epithelial differentiation markers used to study neoplastic and inflammatory diseases. Alterations in CK patterns have been reported in oral potentially malignant and malignant lesions, and their expression is a hallmark of tumour progression [11].

CK8 and CK18 are typically expressed by glandular epithelia, transitional cell epithelium and liver cells but not by stratified squamous epithelium. CK8 and 18 are expressed in foetal buccal mucosa and tongue epithelium until 27 weeks of pregnancy. Therefore, the expression of these CKs by malignant adult mucosa implies a return to an embryonic pattern of expression. Additionally, its expression has been shown to be associated with a poor prognosis [12].

The incidence of oral cancers in the Northeast region of India is significantly high [13]. Hence, the current study was aimed to clinically and histopathologically evaluate the different oral lesions in the region of lower Assam, India with an emphasis on the early diagnosis of premalignant and malignant lesions, which will eventually help in the timely management of patients. Also, to perform IHC with CK8/18 in all cases and explore the relationship of CK8/18 with premalignant and malignant lesions.

The novelty of the present study is that very few studies, like the one by Jaiswal P et al., have been conducted regarding IHC (CK8/18) in oral lesions in India in the past, and none so far in Northeast India [14]. The present study will incentivise further research at the molecular level of similar cases.

MATERIALS AND METHODS

The present hospital-based cross-sectional observational study was conducted in the Departments of Pathology and Otorhinolaryngology, Fakhruddin Ali Ahmed Medical College and Hospital, Barpeta, Assam, India, from September 2020 to August 2021. This work was sanctioned by the Institutional Ethics Committee of Fakhruddin Ali Ahmed Medical College in 2020, vide letter number NO.FAAMC&H/IEC_PG/498/2020/10579. As it was an observational study, all patients presenting with oral cavity lesions within one year were included in this study.

Ninety-three patients with oral cavity lesions who presented in the Otorhinolaryngology Department were included in the current study. After obtaining their informed consent, a thorough history was taken, a detailed physical examination was performed, and relevant laboratory investigations were performed on all subjects, as per the proforma. Informed consent was obtained in the vernacular language (Assamese) from all the patients, and instructions were given regarding filling out the proforma.

Inclusion criteria: Patients, irrespective of age and sex, presenting with oral cavity lesions and resected surgical specimens of the oral cavity that were adequate, and representative of the lesion were included in the study.

Exclusion criteria: Patients diagnosed with oral cavity cancer who were either undergoing treatment or post-treatment were excluded from the study.

Study Procedure

The parameters studied included age, gender, lesion site, histopathological evaluation, and CK8/18 evaluation in dysplastic and malignant cases. The specimens were fixed in 10% formalin and brought to the laboratory. A detailed gross examination was performed and systematically recorded. The specimens were then sectioned from representative areas, and slides were prepared using the following techniques for histopathological examination.

Tissue sections (3-5 mm) were made from different representative areas, and biopsy samples were fixed for 24 hours in 10% formalin. Subsequently, steps of paraffin block preparation were initiated. After section cutting, the selected paraffin-embedded tissue blocks, both benign and malignant, were placed on poly-l-lysine-coated slides for the IHC procedure. The primary antibody used was antibody to CK8/18 (7 mL/RUO, Cell Marque). The positive control in the study was the tissue of infiltrating duct carcinoma breast. The negative control used was sections of the study tissues with no primary antibody incubation.

The IHC interpretation for CK8 and CK18 was performed simultaneously as follows: CK18 forms heteropolymers and is co-expressed with the complementary type II keratin partner CK8, which assembles into keratin. For CK8/18 [14], Cytoplasmic staining in the epithelium was considered positive and cases were categorised into two groups:

- **0:** no expression of CK8/18
- **1:** $\geq 1\%$ positive expression

Intensity of staining: Grading for evaluating the intensity of staining in the epithelium was done as follows:

- 0: negative expression
- +: weak expression
- ++: moderate expression
- +++: maximal expression [14].

STATISTICAL ANALYSIS

All data were collected, compiled, and subjected to suitable statistical analysis, such as one-way ANOVA and the Fisher's exact test, using IBM SPSS Statistics version 28.0. Microsoft Office Word and Excel 2019 were used to generate graphs and tables.

RESULTS

The patients' ages ranged from 9-90 years. The mean \pm SD age was 52.69 \pm 15.81 years. The majority of patients were in the 50-59 years age group with 29 (31.18%) cases, followed by the 60-69 years age group, with 23 (24.73%) cases. Males, 59 (63.4%) were more commonly affected than females, 34 (38.82%), and the male-to-female ratio was 1.73:1.

Among the 93 oral cavity lesions, 24 (25.81%) were located on the buccal mucosa [Table/Fig-1], becoming the most common site in the present study. Seven lesions occurred in more than one

Location	Number (n)
Buccal mucosa	24 (25.81)
Lateral side of tongue	18 (19.35)
Gingiva	15 (16.12)
Soft palate	6 (6.45)
Hard palate	6 (6.45)
Lower lip	5 (5.38)
Ventral aspect tongue	3 (3.22)
Base of tongue	3 (3.22)
Gingivobuccal sulcus	3 (3.22)
Angle of mouth	1 (1.08)
Dorsal aspect tongue	1 (1.08)
Retromolar trigone	1 (1.08)
Angle of mouth and buccal mucosa	2 (2.15)
Gingivobuccal sulcus and retromolar trigone	1 (1.08)
Gingiva and hard palate	1 (1.08)
Angle of mouth and lip	1 (1.08)
Gingiva and mandible	2 (2.18)

[Table/Fig-1]: Distribution of oral cavity lesions as per site.

site. Of these, two lesions occurred concomitantly in the angle of the mouth and buccal mucosa; two lesions in the gingiva and mandible; one lesion each in the gingivobuccal sulcus and retromolar trigone in gingiva and hard palate; and the angle of the mouth and lip. Lymph nodes were received in two cases; in the case with a lesion of the angle of the mouth and lip, supra omohyoid neck nodes were received. Cervical lymph nodes were received for growth in the gingiva and mandible. In both cases, the nodes were free of tumours.

Of the 93 cases, 36 presented with ulceroproliferative, 22 with ulcerative, 16 with proliferative, 14 with well-circumscribed, and five with papillomatous lesions. Sixty-six tissues were received as punch biopsy specimens and 27 as excisional biopsy specimens. On histopathological examination, out of the 93 patients, 31 (33.33%) were found to have benign lesions, while 42 (45.16%) were diagnosed as having malignant lesions, and 20 (21.50%) had dysplastic changes [Table/Fig-2].

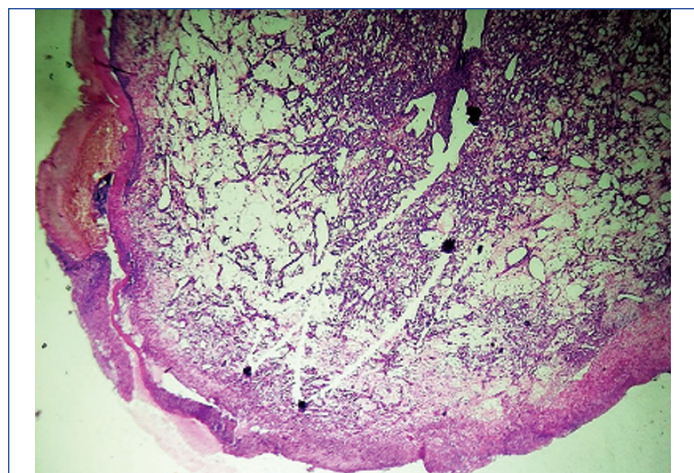
Histological type	Number of cases (n)	Percentage (%)
Well differentiated SCC	18	42.86
Moderately differentiated SCC	21	50
Poorly differentiated SCC	3	7.14
Total	42	100

[Table/Fig-2]: Spectrum of malignant oral cavity lesions.

On histopathological evaluation, all 36 ulceroproliferative cases were malignant; of the 22 ulcerative cases, 15 were benign, five were dysplastic, and two were malignant. Four of the 16 proliferative lesions were malignant, and 12 were dysplastic. Of the 14 well-circumscribed lesions, 11 were benign, and three were dysplastic. Of the five papillomatous lesions, all were benign.

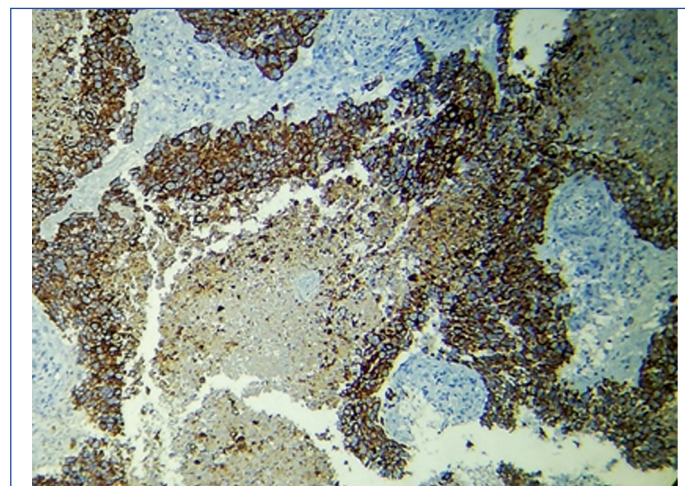
The mean ages in the benign, dysplasia, and malignant groups were 42±17.42 years, 56.50±13.73 years and 58.78±10.95 years, respectively. The differences were not found to be statistically significant (p-value>0.10) by a one-way ANOVA test. On histopathological examination, benign lesions were most common in the age group of 30-39 years with 9 (9.67%) cases, followed by 50-59 years with 7 (7.52%) cases. Malignant lesions were most common in the age group of 60-69 years with 15 (16.12%) cases, followed by 50-59 years with 14 (15.05%) cases. Dysplasia was most common in the age group of 50-59 years, with 8 (8.60%) cases.

Of the 31 benign oral cavity lesions, 14 cases were of pyogenic granuloma [Table/Fig-3], 10 of fibrous epulis, three of pseudoepitheliomatous hyperplasia, and four of squamous papilloma. Among the 42 malignant oral cavity lesions, the most frequent was moderately differentiated SCC with a frequency of 21 cases (50%), followed by well-differentiated SCC with 18 cases, including one case of verrucous carcinoma. Poorly differentiated SCC was the least frequent, with 3 (7.14%) cases [Table/Fig-2].



[Table/Fig-3]: Photomicrograph showing pyogenic granuloma (H&E, 10x).

Immunohistochemistry with CK8/18 was performed in all 93 cases of oral cavity lesions, using infiltrating duct carcinoma of the breast as a positive control [Table/Fig-4]. Staining was positive in 33 of the 42 malignant cases, four of the 20 dysplasia cases, and all the benign cases, which tested negative for IHC of CK8/18 [Table/Fig-5].

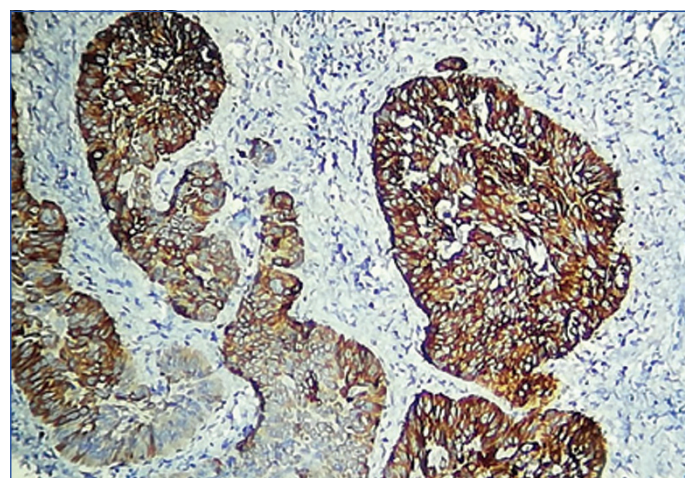


[Table/Fig-4]: Photomicrograph showing positive control (Breast infiltrating duct carcinoma) for CK8/18 (IHC, 10x).

Result	Benign		Dysplasia		Malignant	
	n	%	n	%	n	%
Positive	0	0	4	20	33	78.57
Negative	31	100	16	80	9	21.43
Total (93)	31	100	20	100	42	100

[Table/Fig-5]: Distribution of CK8/18 expressions in benign, dysplastic and malignant oral cavity lesions.

The intensity of CK8/18 expression was interpreted as described in the materials and methods [14]. Weak intensity of CK8/18 was observed in 3/20 (15%) of dysplastic cases, 3/18 (16.7%) of well-differentiated cases, and 1/3 (33.33%) of poorly differentiated oral SCC. Moderate intensity of CK8/18 was found in 1/20 (5%) of dysplastic cases, 9/18 (50%) of well-differentiated cases [Table/Fig-6], 5/21 (23.8%) of moderately differentiated cases, and 2/20 (66.66%) of poorly differentiated oral SCC [Table/Fig-7]. Maximal intensity of CK8/18 was observed in 13/21 (62%) of moderately differentiated oral SCC [Table/Fig-8,9].

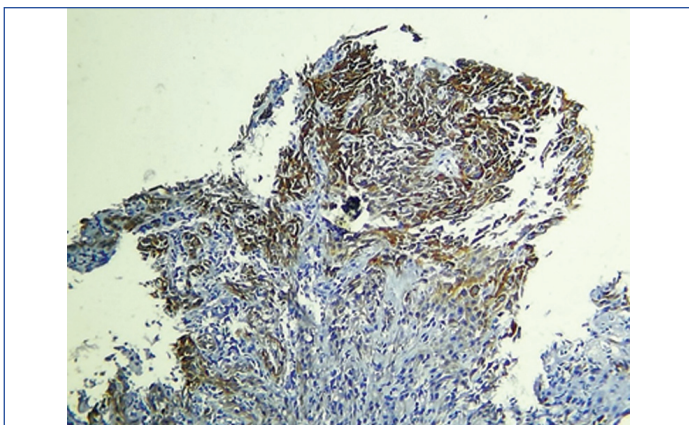


[Table/Fig-6]: Photomicrograph showing moderate positivity for CK8/18 in well-differentiated SCC (IHC, 10x).

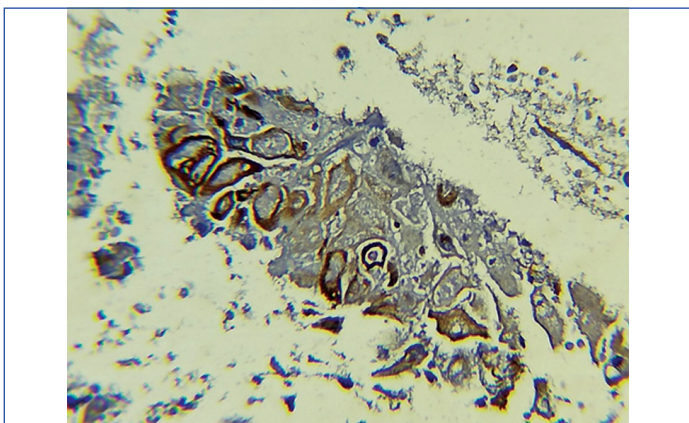
The expression of CK8/18 was significantly higher in OSCCs (p-value<0.0001) than in the dysplastic group [Table/Fig-10].

DISCUSSION

It is frequently assumed that oral carcinogenesis involves Potentially Premalignant Oral Epithelial Lesions (PPOELs) that undergo a gradual



[Table/Fig-7]: Photomicrograph showing moderate positivity for CK8/18 in poorly differentiated SCC (IHC, 10x).



[Table/Fig-8]: Photomicrograph showing moderate positivity for CK8/18 in moderately differentiated SCC (IHC, 10x).

make CK8 a valuable tool in the early detection of premalignant lesions [17].

Ninety-three cases presented as oral cavity lesions in the present study were diagnosed as benign, dysplastic and malignant lesions. It was observed that oral cavity lesions vary according to age, sex, site, nature and frequency.

The study included patients ranging from 9-90 years of age. The most common age group affected was noted between 50-59 years (31.18%) with a mean age of 52.69±15.81, comparable to the study of Chiang TE et al., where the mean age was 56.55±12.93 years [18]. However, in Pudasaini S and Baral R, the age ranged from 12-68 years with a mean of 46 years, and the most common age group (47.6%) was 20-40 years, followed by the age group above 60 years (19%) [19].

Blochowiak K et al., conducted a study on oral cavity lesions in 2019 and found the mean age for dysplasia (54.3±2.6 years) comparable to the present study (56.50±13.73 years) [20]. However, the mean ages were lower in both the benign and malignant groups than in Blochowiak K et al., [20].

In the present study, oral cavity lesions were more common in males with a male-to-female ratio of 1.73:1. This finding is consistent with other studies like Tatli U et al., and Jahanbani J et al., [21,22]. Tatli U et al., conducted a retrospective analysis on patients who were admitted with oral cavity pathology and underwent biopsy procedures between 2007 and 2011 [21]. A total of 2718 cases were included, and they found oral cavity lesions more common in males.

Jahanbani J et al., studied 598 patients referred to the Departments of Oral Pathology and of Oral Medicine, Islamic Azad University, School of Dentistry, and they too found a higher incidence in males [22]. On the contrary, Blochowiak K et al., found no difference in the incidence of lesions based on gender [20].

Histopathological type	Intensity of CK8/18							
	Negative		Weak		Moderate		Maximal	
	Number of cases, n	%	Number of cases, n	%	Number of cases, n	%	Number of cases, n	%
Dysplasia (n=20)	16	80	3	15	1	5	0	0
Well differentiated SCC (n=18)	6	33.3	3	16.7	9	50	0	0
Moderately differentiated SCC (n=21)	3	14.3	0	0	5	23.8	13	62
Poorly differentiated SCC (n=3)	0	0	1	33.33	2	66.66	0	0

[Table/Fig-9]: Distribution of CK8/18 IHC expression intensity in dysplastic and malignant oral cavity lesions.

HP diagnosis	Negative		Positive		Total	p-value	Relative risk	95% CI
	n	%	n	%				
Dysplasia	16	25.8	4	6.4	20 (32.26%)	<0.0001*	3.733	2.010-6.935
Malignant	9	14.5	33	53.2	42 (67.74%)			
Total	25 (40%)		37 (60%)		62 (100%)			

[Table/Fig-10]: Fisher's exact test for CK8/18 expressions in dysplasia and malignant groups.

*The p-value <0.05 was considered statistically significant value

progression beginning with hyperplasia and evolving through stages of mild dysplasia, moderate dysplasia, severe dysplasia, Carcinoma In Situ (CIS) and finally carcinoma after cellular invasion through the basement membrane. In reality, it is likely that, in some cases, the course of oral cancer does not occur in such an orderly manner [15].

Conventional Oral Examination (COE) alone is insufficient for risk stratification [16]. Excisional biopsy, when done for smaller lesions, can prevent sampling bias. However, the possibility of incomplete excision exists in malignant lesions, and the procedure might be overtreatment in the case of benign lesions. Therefore, an incisional biopsy is generally preferred, though it cannot assess the entire lesion. This leads to sampling bias, causing underdiagnosis or misdiagnosis, particularly in multifocal, large, or non homogeneous lesions.

As CK8 is absent in normal mucosa of the oral cavity, its expression differentiates dysplastic lesions and carcinoma. These features

In this part of Assam, men may indulge more in risk factors such as tobacco and areca nut consumption, as well as, heavy alcohol consumption [23,24]. Another reason might be the easy accessibility of health services in the area and increased awareness about diseases due to the high literacy rates among men in the state.

In the present study, the most commonly involved site was the buccal mucosa (25.81%), followed by the lateral aspect of the tongue (19.35%) and gingiva (16.12%). This result is comparable with that of Torabi M et al., who found that the most commonly involved site for oral cavity lesions was the lower lip, followed by the buccal mucosa [25].

Malignant lesions (45.16%) were more common than benign lesions (33.33%) and dysplastic lesions (21.50%) among all the oral cavity lesions. This result is consistent with Gupta I et al., and, Thomas

BM and Rajagopal I, but inconsistent with Blochowiak K et al., and, Pudasaini S and Baral R, where benign lesions were more common than malignant ones [19,20,26,27].

The most common benign tumour was pyogenic granuloma (45.16%), followed by fibrous epulis (32.26%). This observation is comparable to the reports of Thomas BM and Rajagopal I, with pyogenic granuloma being the most frequent (42.85%), but differs from Gupta I et al., where benign keratosis and Agrawal R et al., Pseudoepitheliomatous hyperplasia were the commonest benign lesions, respectively [26-28]. Priyanka S et al., found squamous papilloma to be the most common benign lesion [29]. In the present study, all the malignant oral cavity lesions were SCC, consistent with the findings of Gupta I et al., Thomas BM and Rajagopal I, and Priyanka S et al., [26,27,29].

In the present study, moderately differentiated SCC was the most common (50%), followed by well-differentiated SCC (42.86%) and poorly differentiated SCC (7.14%). This result is consistent with Pires FR et al., and Lin NC et al., but inconsistent with Padma R et al., where well-differentiated SCC was most frequent [30-32].

The stage of oral SCC at the time of diagnosis is the most important prognostic factor [33]. Oral SCC is most frequently diagnosed late in the course of the disease because affected persons fail to seek professional, timely medical advice, either because they are unaware of the significance of early signs and symptoms or the health implications of oral SCC [34].

Immunohistochemistry for CK8/18 was done in all 93 cases of oral cavity lesions. Cytoplasmic staining was taken as positive in the epithelium. Staining was positive in 33/42 (78.57%) malignant cases, 4/20 (20%) dysplasia cases, and all the benign cases were negative for IHC of CK8/18.

Kale AD et al., in their study, found that the expression of CK8/18 was negative in all Normal Oral Mucosa (NOM), but its expression was enhanced in OSCC (10%), which is progressing toward poorly differentiated than well-differentiated [35]. However, the expression of CK8/18 was enhanced in the epithelium of the majority of tissues of Apparently Normal-looking Mucosa (ANM) (80%). Its enhanced expression was also noted in all ANMs, which showed severe dysplasia. Previous research also supports that the expression of CK8/18 is enhanced in leukoplakia with dysplasia compared to without dysplasia and seems to play an important role in progressing to OSCC. These findings corroborate the present study.

Nanda KDS et al., also found similar results with increased expression of CK8 and CK18 seen in dysplasia, OSF, and OSCC [36]. The present results corroborate the findings of Jaiswal P et al., who found that the expression of CK8/18 was 57.81% (74/128) in oral SCC. CK8 was absent in 20 (100%) control tissue [14].

In a study by Sihmar SS, strong expression of CK8/18 was also noted in oral potentially malignant diseases and oral SCC [37]. Jaiswal P et al., also found no expression of CK8 in 30/58 (51.72%) cases of well-differentiated, 20/50 (40%) of moderately differentiated, and 4/20 (20%) of poorly differentiated oral SCC. In contrast, in the present study, 33.3% of well-differentiated, 14.3% of moderately differentiated, and 0% of poorly differentiated showed no expression of CK8/18 [14].

In the present study, maximal intensity for CK8/18 was observed in 62% of the moderately differentiated SCC. In comparison, well-differentiated SCC showed mild intensity (16.7%), and poorly differentiated SCC exhibited mostly high intensity (66.66%). These findings contrast with those of Jaiswal P et al., where mild intensity of CK8 was observed in 10 out of 58 (17.24%) well-differentiated and 6 out of 50 (12%) moderately differentiated oral SCCs [14]. Moderate intensity of CK8 was observed in 6 out of 58 (10.34%) well-differentiated, 8/50 (16%) moderately differentiated, and 4/20 (20%) poorly differentiated oral SCCs. Maximal intensity of CK8

was observed in 12/20 (20.7%) well-differentiated, 16/50 (32%) moderately differentiated, and 12/20 (60%) poorly differentiated oral SCCs.

Limitation(s)

The present study's limitations include the inability to provide radiological correlation as most were small biopsies done for diagnostic purposes rather than to assess the extent of tumour spread. Those with dysplasia or malignancy were referred to cancer centres for further evaluation and treatment. Additionally, the sample size was limited, but previous and newer studies exist with far smaller sample sizes than the present one. Furthermore, as very few studies have been conducted regarding IHC (CK8/18) in oral lesions in India in the past, and none so far in Northeast India, the current study will be an incentive for further research at the molecular level of similar cases.

CONCLUSION(S)

In conclusion, the present study on oral cavity lesions in the Lower Assam region in India highlighted the significance of clinical histopathological, and immunohistochemical evaluations, particularly with CK8/18 staining. It was found that there was predominance of lesions on the buccal mucosa, with moderately differentiated SCC being the most common malignant type. CK8/18 expression showed a notable association with malignant lesions, especially in moderately differentiated SCC, suggesting its potential as a diagnostic marker. These findings contribute to a better understanding of oral cavity pathologies and may aid in early detection and management strategies.

REFERENCES

- [1] Saberian E, Jenča A, Petrášová A, Jenčová J, Jahromi RA, Seiffadini R. Oral cancer at a glance. *Asian Pacific Journal of Cancer Biology*. 2023;8(4):379-86.
- [2] Groeger S, Meyle J. Oral mucosal Epithelial cells. *Front Immunol*. 2019;10:208.
- [3] Kosam S, Kujur P. Pattern of oral cavity lesion: A retrospective study of 350 cases. *International Journal of Scientific Study*. 2016;4(3):65-69.
- [4] Singhal N, Khurana U, Handa U, Punia RPS, Mohan H, Dass A, et al. Intraoral and oropharyngeal lesions: role of fine needle aspiration cytology in the diagnosis. *Indian J Otolaryngol Head Neck Surg*. 2015;67(4):381-87.
- [5] Pahwa V, Nair S, Shetty RS, Kamath A. Prevalence of oral premalignant lesions and its risk factors among the adult population in Udipi Taluk of Coastal Karnataka, India. *Asian Pac J Cancer Prev*. 2018;19(8):2165-70.
- [6] Frohwitter G, Buerger H, Fillies T. Cytokeratin and protein expression patterns in squamous cell carcinoma of the oral cavity provide evidence for two distinct pathogenetic pathways. *Oncol Lett*. 2016;12(1):107-13.
- [7] Tandon A, Bordoloi B, Jaiswal R, Srivastava A, Singh RB, Shafique U. Demographic and clinicopathological profile of oral squamous cell carcinoma patients of North India: A retrospective institutional study. *SRM Journal of Research in Dental Science*. 2018;9:114-18.
- [8] Sharma P, Deb T, Ray JG, Singh AK, Gupta G, Das A, et al. Oral squamous cell carcinoma profile in North-Eastern regions of India from habits to histopathology: A hospital-based study. *Natl J Maxillofac Surg*. 2018;9:56-60.
- [9] Pina AR, Fonseca FP, Pontes FS, Pontes HA, Pires FR, Mosqueda-Taylor A, et al. Benign epithelial oral lesions - association with human papillomavirus. *Med Oral Patol Oral Cir Bucal*. 2019;24(3):e290-e295.
- [10] Lerman MA, Almazrooa S, Lindeman N, Hall D, Villa A, Woo SB. HPV-16 in a distinct subset of oral epithelial dysplasia. *Mod Pathol*. 2017;30:1646-54.
- [11] Chu PG, Weiss LM. Keratin expression in human tissues and neoplasms. *Histopathology*. 2002;40(5):403-39.
- [12] Tinca AC, Cocuz IG, Şincu MC, Niculescu R, Sabău AH, Chiorean DM, et al. CK 8/18: the key to differentiating intracutaneous lesions with pagetoid features. *Rom J Morphol Embryol*. 2021;62(3):757-63.
- [13] Sharma JD, Baishya N, Katakai AC, Kalita CR, Das AK, Rahman T. Head and neck squamous cell carcinoma in young adults: A hospital-based study. *Indian Journal of Medical and Paediatric Oncology*. 2019;40:S18-22.
- [14] Jaiswal P, Yadav YK, Sinha SS, Singh MK. Expression of Cytokeratin 8 in oral squamous cell carcinoma. *Indian Journal of Pathology and Oncology*. 2018;5(1):55-60.
- [15] Yang EC, Tan MT, Schwarz RA, Richards-Kortum RR, Gillenwater AM, Vigneswaran N. Noninvasive diagnostic adjuncts for the evaluation of potentially premalignant oral epithelial lesions: Current limitations and future directions. *Oral Surg Oral Med Oral Pathol Oral Radiol*. 2018;125(6):670-81.
- [16] Patel KJ, De Silva HL, Tong DC, Love RM. Concordance between clinical and histopathologic diagnoses of oral mucosal lesions. *J Oral Maxillofac Surg*. 2011;69(1):125-33.

- [17] Reichart PA, Philipsen HP. Oral erythroplakia- A review. *Oral Oncol.* 2005;41(6):551-61.
- [18] Chiang TE, Lin YC, Wu CT, Yang CY, Wu ST, Chen YW. Comparison of the accuracy of diagnoses of oral potentially malignant disorders with dysplasia by a general dental clinician and a specialist using the Taiwanese Nationwide Oral Mucosal Screening Program. *PLoS One.* 2021;16(1):e0244740.
- [19] Pudasaini S, Baral R. Oral cavity lesions: A study of 21 cases. *Journal of Pathology of Nepal.* 2011;1(1):49-51.
- [20] Blochowiak K, Farynowska J, Sokalski J, Wyganowska-Świątkowska M, Witmanowski H. Benign tumours and tumour-like lesions in the oral cavity: a retrospective analysis. *Postepy Dermatol Alergol.* 2019;36(6):744-51.
- [21] Tatli U, Erdogan O, Uguz A, Ustun Y, Sertdemir Y, Damlar I. Diagnostic concordance characteristics of oral cavity lesions. *Scientific World Journal.* 2013;2013:785929. Doi: 10.1155/2013/785929.
- [22] Jahanbani S, Sandvik L, Lyberg T, Ahlfors E. Evaluation of oral mucosal lesions in 598 referred Iranian patients. *Open Dent J.* 2009;3:42-47.
- [23] Muttagi SS, Chaturvedi P, Gaikwad R, Singh B, Pawar P. Head and neck squamous cell carcinoma in chronic areca nut chewing Indian women: Case series and review of literature. *Indian J Med Paediatr Oncol.* 2012;33(1):32-35.
- [24] Johnson NW, Jayasekara P, Amarasinghe AA. Squamous cell carcinoma and precursor lesions of the oral cavity: Epidemiology and aetiology. *Periodontol* 2000. 2011;57(1):19-37.
- [25] Torabi M, Afshar MK, Afshar HM, Mohammadzadeh I. Correlation between clinical and histopathologic diagnosis of oral potentially malignant disorder and oral squamous cell carcinoma. *Pesqui Bras Odontopediatria Clin Integr.* 2021;21:e0143. Available from: <https://doi.org/10.1590/pboci.2021.068>.
- [26] Gupta I, Rani R, Suri J. Histopathological spectrum of oral cavity lesions - A tertiary care experience. *Indian J Pathol Oncol.* 2021;8(3):364-68.
- [27] Thomas BM, Rajagopal I. Histopathological spectrum of oral cavity lesions in a tertiary care hospital in South India. *Annals of Pathology and Laboratory Medicine.* 2019;6(3):A163-16.
- [28] Agrawal R, Chauhan A, Kumar P. Spectrum of oral lesions in a tertiary care hospital. *J Clin Diagn Res.* 2015;9(6):EC11-EC13.
- [29] Priyanka S, Karuna G, Sunita S, Ajay Y. A study of clinico-pathological spectrum of oral cavity lesions at a tertiary care hospital. *Journal of Medical Science and Clinical Research.* 2018;6(4):267-76.
- [30] Pires FR, Ramos AB, Oliveira JB, Tavares AS, Luz PS, Santos TC. Oral squamous cell carcinoma: Clinicopathological features from 346 cases from a single oral pathology service during an 8-year period. *J Appl Oral Sci.* 2013;21(5):460-67.
- [31] Lin NC, Hsien S, Hsu JT, Chen MYC. Impact on patients with oral squamous cell carcinoma in different anatomical subsites: A single-center study in Taiwan. *Sci Rep.* 2021;11:15446.
- [32] Padma R, Kalaivani A, Sundaresan S, Sathish P. The relationship between histological differentiation and disease recurrence of primary oral squamous cell carcinoma. *J Oral Maxillofac Pathol.* 2017;21(3):461.
- [33] Warnakulasuriya S. Global epidemiology of oral and oropharyngeal cancer. *Oral Oncology.* 2009;45(4):309-16.
- [34] Scully C, Bagan J. Oral squamous cell carcinoma overview. *Oral Oncol.* 2009;45(4-5):301-08.
- [35] Kale AD, Mane DR, Babji D, Gupta K. Establishment of field change by expression of cytokeratins 8/18, 19 and MMP-9 in an apparently normal oral mucosa adjacent to squamous cell carcinoma: A immunohistochemical study. *J Oral Maxillofac Pathol.* 2012;16(1):10-15.
- [36] Nanda KDS, Ranganathan K, Devi U, Joshua E. Increased expression of CK8 and CK18 in leukoplakia, oral submucous fibrosis and oral squamous cell carcinoma: An immunohistochemistry study. *Oral Surg Oral Med Oral Pathol Oral Radiol.* 2012;113(2):245-53.
- [37] Sihmar SS, Ramalingam K, Rathi S, Solkhe M, Monu P. Immunohistochemical expression of Ck8 and Ck18 in oral potentially malignant disorders and oral squamous cell carcinoma -a retrospective study on 70 sample. *Journal of Pharmaceutical Negative Results.* 2022;13(4):1153-69.

PARTICULARS OF CONTRIBUTORS:

1. Consultant Pathologist and Laboratory Head, Department of Pathology, Institute of Urology and Kidney Diseases, Guwahati, Assam, India.
2. Professor and Head, Department of Pathology, Fakhruddin Ali Ahmed Medical College and Hospital, Guwahati, Assam, India.
3. Associate Professor, Department of Pathology, Nagaon Medical College and Hospital, Guwahati, Assam, India.
4. Associate Professor, Department of Pathology, Nagaon Medical College and Hospital, Guwahati, Assam, India.

NAME, ADDRESS, E-MAIL ID OF THE CORRESPONDING AUTHOR:

Barnali Das,
House No. 26, Namghar Path 2, Wireless,
Dispur, Kamrup (M), Guwahati-781006, Assam, India.
E-mail: drbarnali12@gmail.com

PLAGIARISM CHECKING METHODS: [Jain H et al.]

- Plagiarism X-checker: Jan 25, 2024
- Manual Googling: Mar 20, 2024
- iThenticate Software: May 02, 2024 (13%)

ETYMOLOGY: Author Origin**EMENDATIONS:** 7**AUTHOR DECLARATION:**

- Financial or Other Competing Interests: None
- Was Ethics Committee Approval obtained for this study? Yes
- Was informed consent obtained from the subjects involved in the study? Yes
- For any images presented appropriate consent has been obtained from the subjects. Yes

Date of Submission: **Jan 25, 2024**Date of Peer Review: **Mar 18, 2024**Date of Acceptance: **May 03, 2024**Date of Publishing: **Aug 01, 2024**